

## Chronic traumatic diaphragmatic hernia: A case report

### Hernia diafragmática traumática crónica: a propósito de un caso

**Rudy Zambrano Morales**

Portoviejo Medical Clinic, Av. José Manuel Urbina. Portoviejo, Ecuador  
rudizambrano91@gmail.com

Caso clínico

Recibido: 06-04-2017

Aceptado: 28-09-2017

#### **Abstract**

A diaphragmatic hernia is a very rare pathology, and clinical suspicion is needed for its diagnosis, and in cases of closed trauma it is much more frequently. For a correct diagnosis in chronic cases we should focus the importance of personal record and imaging studies, because the signs and symptoms may go unnoticed. In this sense, the objective is to describe the main clinical manifestations a diaphragmatic hernia, its approach and, diagnosis. The patient went to the Portoviejo Medical Clinic for a different reason and when performing a chest x-ray, the diagnosis of chronic diaphragmatic hernia was outlined. Currently, the treatment of choice is laparoscopy, but the patient presented complications and had to undergo an open surgical procedure. Conclusions: in order to reduce mortality and complications, a correct diagnosis must be made, recognizing by signs, symptoms and images if we are facing an acute or chronic condition; and always take into account personal record, as that can give the clue that helps in the diagnosis and early treatment.

**Keywords:** Chronic traumatic diaphragmatic hernia; complications; closed chest trauma.

#### **Resumen**

La hernia diafragmática es una patología muy poco frecuente, y se necesita de la sospecha clínica para su diagnóstico, en casos de trauma cerrado con mayor frecuencia. Para un diagnóstico correcto en casos crónicos se debe focalizar la importancia de los antecedentes personales y los estudios de imagen, porque los signos y síntomas pueden pasar desapercibidos. En tal sentido, el objetivo es describir las principales manifestaciones clínicas de la hernia diafragmática, su abordaje y diagnóstico. El paciente acudió a la Clínica Portoviejo Medical por un motivo distinto y al realizar una radiografía de tórax, se perfiló el diagnóstico de hernia diafragmática crónica. Actualmente el tratamiento de elección es la laparoscopia, pero el paciente presentó complicaciones y se tuvo que realizar un procedimiento quirúrgico a cielo abierto. Se concluye que para poder disminuir la mortalidad y las complicaciones, se debe realizar un diagnóstico correcto, reconocer por signos, síntomas e imágenes si estamos frente a un cuadro agudo o crónico; y siempre tomar en cuenta los

antecedentes personales, pues eso puede dar la pista que ayude al diagnóstico y tratamiento temprano.

**Palabras clave:** Hernia diafragmática traumática crónica; complicaciones; trauma cerrado de tórax.

## Introduction

Diaphragmatic hernias are defined as the passage of the abdominal contents into the thoracic cavity through a defect in the diaphragm. These are divided into congenital (anterior or Morgagni and posterolateral or Bochdalek) and acquired (traumatic). Of these, congenital diaphragmatic hernias produce hypoplasia with pulmonary hypertension in the new born, which causes physiological alterations that seriously threaten life. The diagnosis a diaphragmatic hernia can be performed from the prenatal stage through different imaging techniques. Bochdalek described in 1848 the embryology of a diaphragmatic hernia that today bears his name. A Bochdalek hernia is a congenital posterolateral defect of the diaphragm located on the left side in 70 to 90 % of the cases. It is usually present with acute respiratory failure<sup>1</sup>.

The incidence of traumatic diaphragmatic hernia is uncommon, ranging from 0.8 to 8.0 % and the mortality rate varies between 16 and 33 % according to the time of diagnosis, thus, the faster the diagnosis is made, the lower the range of morbi mortality. There have been reports of traumatic lesions of the diaphragm not detected appropriately, which remain asymptomatic until it is accompanied by complications<sup>2</sup>.

The urgency of the diagnosis arises from cases of intestinal strangulation, volvulus or compromise of organs or situations that affect the venous return and cardiac output by the compression of the intrathoracic intestinal loops or by the great gastric distension with hemodynamic or respiratory problems that they are observed in the evolution course of the disease<sup>3</sup>. In hemodynamically stable patients, video laparoscopy and video thoracoscopy allow the diagnosis and in many cases the treatment of the diaphragmatic lesion. In most cases, the suture of the borders of the diaphragmatic wound is sufficient to correct the lesion. In large diaphragmatic defects the use of prostheses may be necessary<sup>4</sup>.

With the aim of describing the main clinical manifestations of diaphragmatic hernia, its approach and diagnosis, we present the case of a patient with a record of multiple traumas due to traffic accidents, in which left diaphragmatic hernia was diagnosed incidentally. Emphasis is placed on the most important aspects of this disease and the evolution that the patient had.

## Presentation of the case

A 52-year-old male, mestizo race, with a record of three previous traffic accidents (fracture of right tibia and clavicle); who comes to our health home after suffering a traffic accident: he was riding a motorcycle and was hit hard on the left leg by a car. At the time of admission he was stable, afebrile, manifesting intense pain in the left leg and functional impotence.

### Physical exam

Glasgow 15, blood pressure: 120/70 mmHg, heart Rate: 95 per minute, respiratory rate: 18 per minute, oxygen saturation: 98 %, multiple lacerations are seen on the face, arms and legs and abolition of the vesicular murmur in the left pulmonary base.

An exposed fracture of the left tibia is observed at the middle third level, with soft tissue exposure and active bleeding. Enough reason for consultation with traumatology and we decide to perform surgical cleaning, reduction and osteosynthesis with the placement of external tutors.

### Complementary test

Hematological biometrics: Red blood cells 3.630.000, Hemoglobin 11.9 g/dL, Hematocrit 35.8 %, Platelets 170.000, Leukocytes 10.230, PMN 73.6 %, Lymphocytes 18.4 %, Monocytes 7.3 %, Basophils 0.2 %, EKG: Sinus rhythm.

### Image studies

#### Radiographies

AP and left leg side: Multifragmentary fracture the left tibial shaft.

Thorax standard: Basal mass is observed in the left lung, deviation of the cardiac silhouette and trachea to the right (See Figure 1).

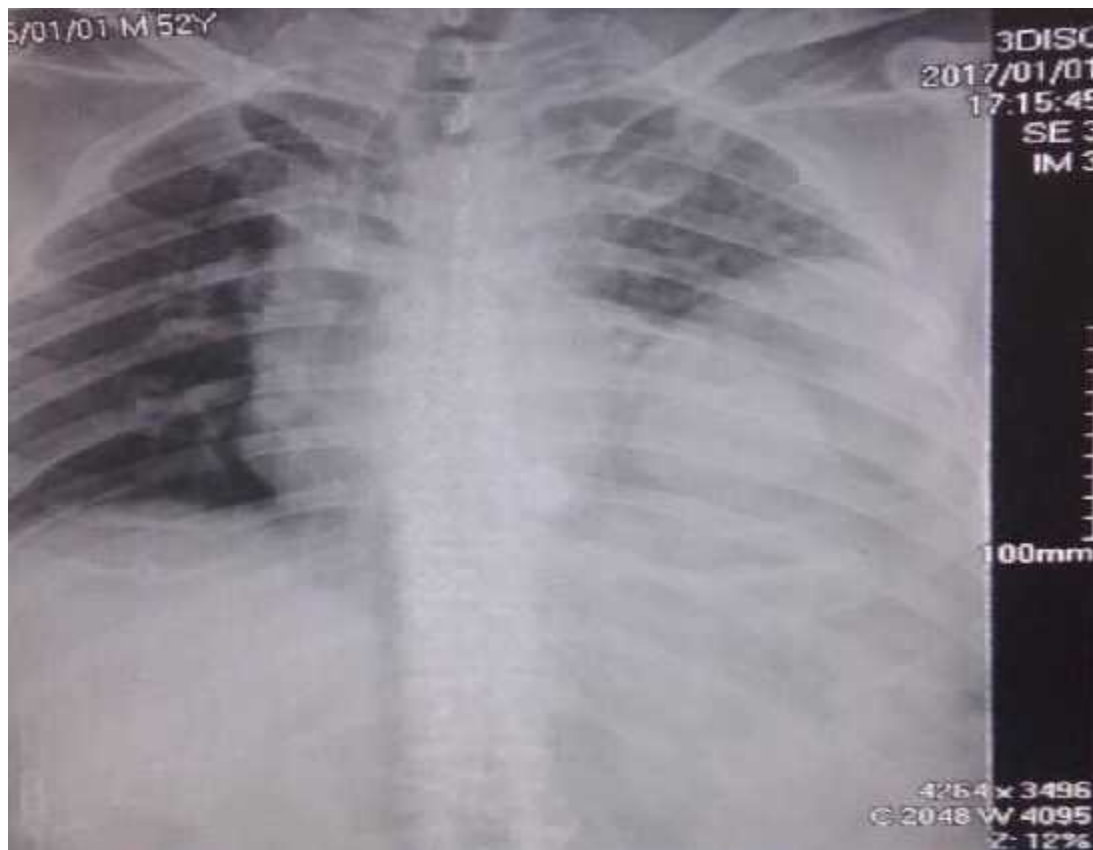


Figure 1. Standard Chest XR.

**Procedure**

He was carried to the operating ward and we performed a surgical cleaning, reduction and osteosynthesis and placement of external tutors. The approximate bleeding was 1000 mL. It concludes without complications and two concentrates of red blood cells were passed.

**First post-surgical day**

Patient with favorable evolution, conscious, begins feeding with soft a diet.

**Post-surgical day**

Stable during morning hours, general diet at lunch. Subsequent to this, Glasgow 15, with mild respiratory distress, tachypnoea (23 per minute), tachycardia (118 per minute), has high arterial pressures ranging from 150/80 to 180/100 mmHg, oxygen saturation to the environment 88 %, for this reason we decided to put oxygen, 3 liters per minute through oxygen mask. Vesicular murmur abolished in left hemithorax. It is maintained with high arterial pressures and support of oxygen.

**Supplementary examinations**

Red blood cells 3 640000 mm<sup>3</sup>, Hemoglobin 11.6 g/dL, Hematocrit 34 %, Platelets 112.000 mm<sup>3</sup>, Leukocytes 10.390 mm<sup>3</sup>, PMN 75.3 %, Lymphocytes 11.5 %, Monocytes 10.9 %, Basophils 0.10 %, Prothrombin time 12.50 seconds, Thromboplastin time 26.30 seconds, D Dimer 1553 ng/mL, TGO 125 IU/L, TGP 69 IU/L, Urea 39 mg/dL, Creatinine 0.82 mg/dL.

Thoracoabdominal TAC is performed. Figure 2 shows in the left, a diaphragmatic hernia, the left lung collapsed, presence of stomach and peritoneal fat in the left hemithorax, stable fracture of eighth left rib.

Thoracic surgery was reported, and after assessment by a specialist, he decides to intervene and perform left lateral emergency thoracotomy and diaphragmatic plasticity after exploring and finding a defect of 15 cm in diameter, and stomach and omentum in left hemithorax, reducible, no signs of ischemia (See Figure 3 and 4).

The operation concludes without any problem, before leaving the drainage pipe. On the second postoperative day, a standard chest X-Ray is performed (See Figure 5), where the trachea is observed in the normal position, as well as the left hemithorax. Subsequently, the patient was with good evolution until medical discharge on the 5th postoperative day.

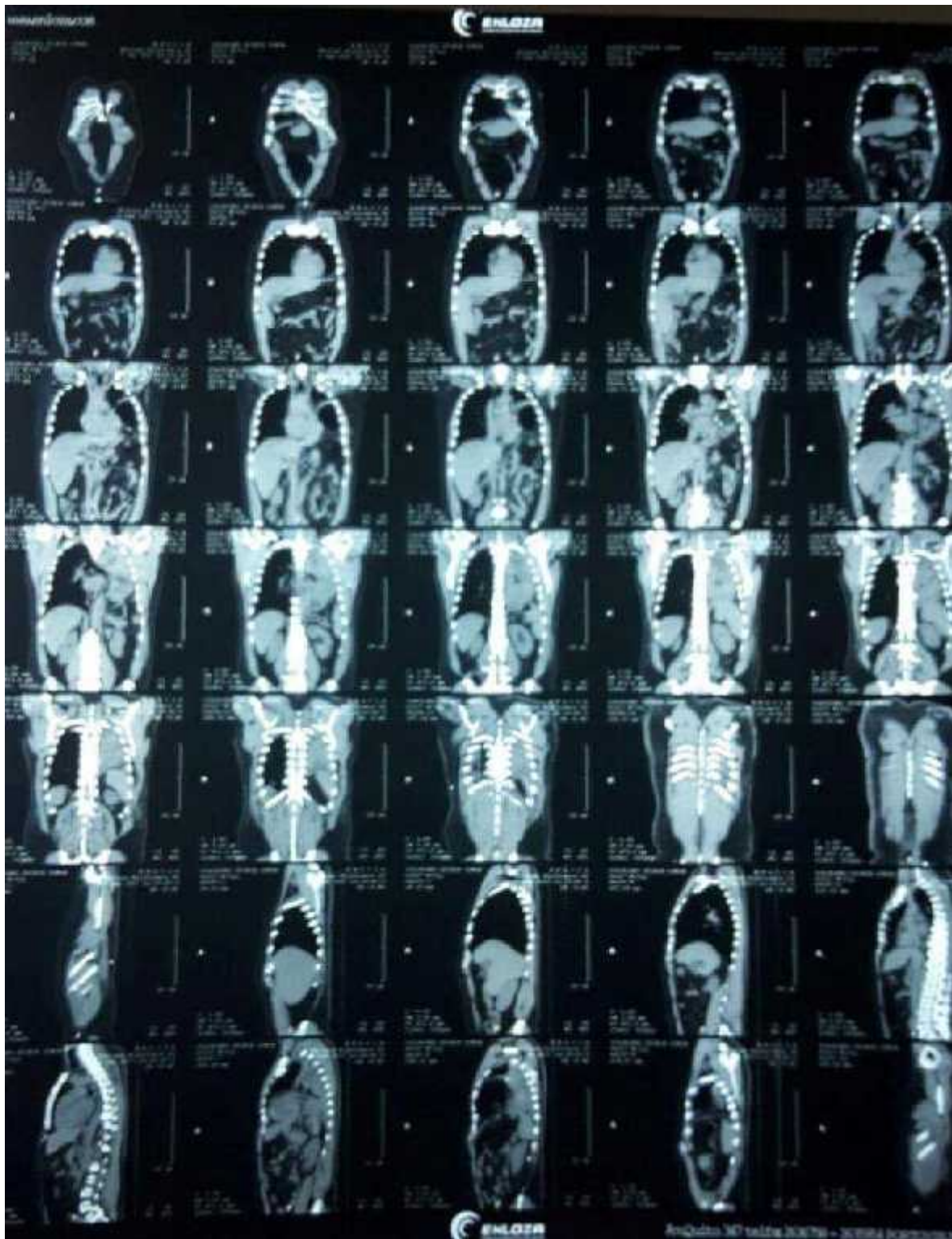


Figure 2. Thoracoabdominal tomography. Frontal and side view.

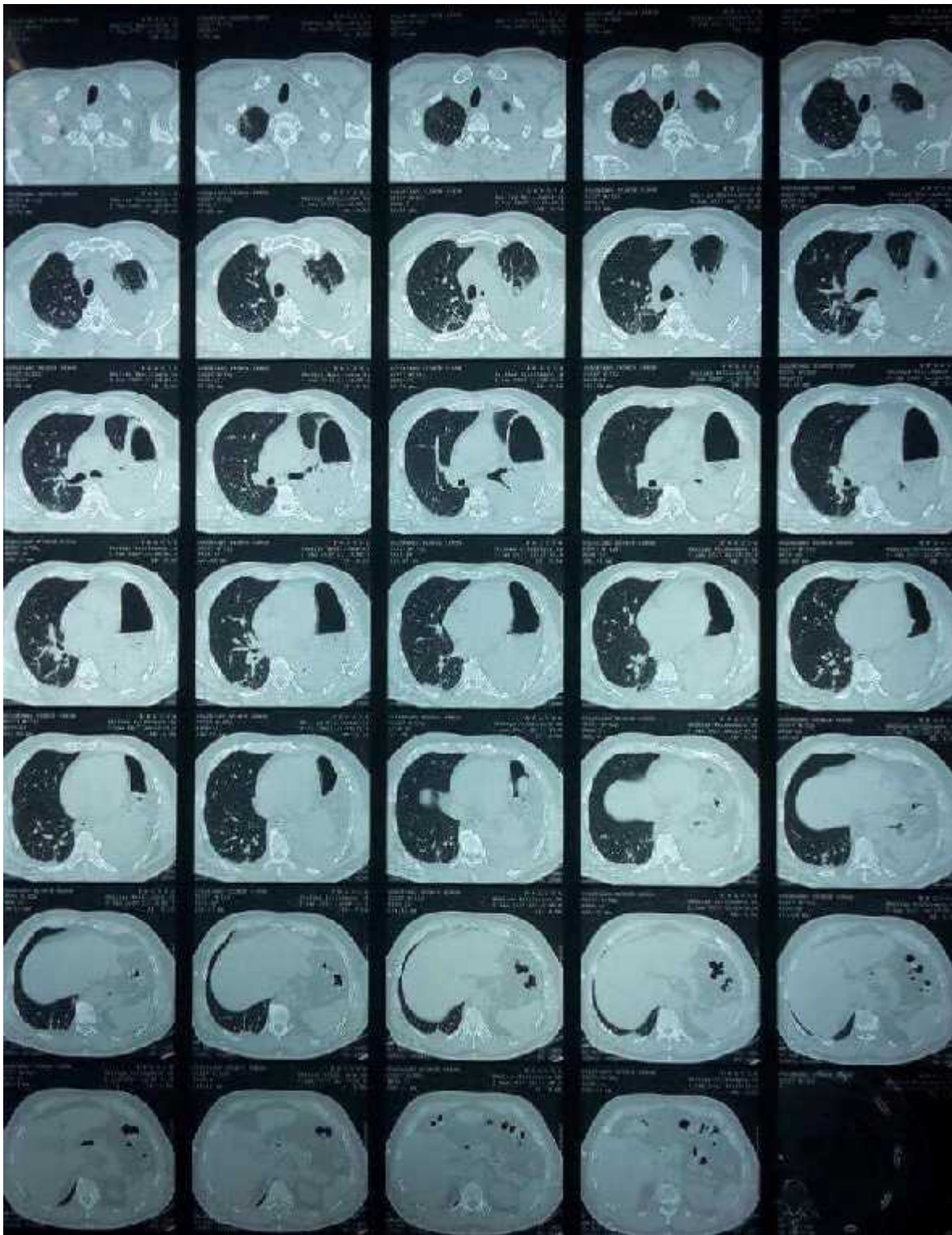


Figure 3. Thoracic tomography. Axial Section.

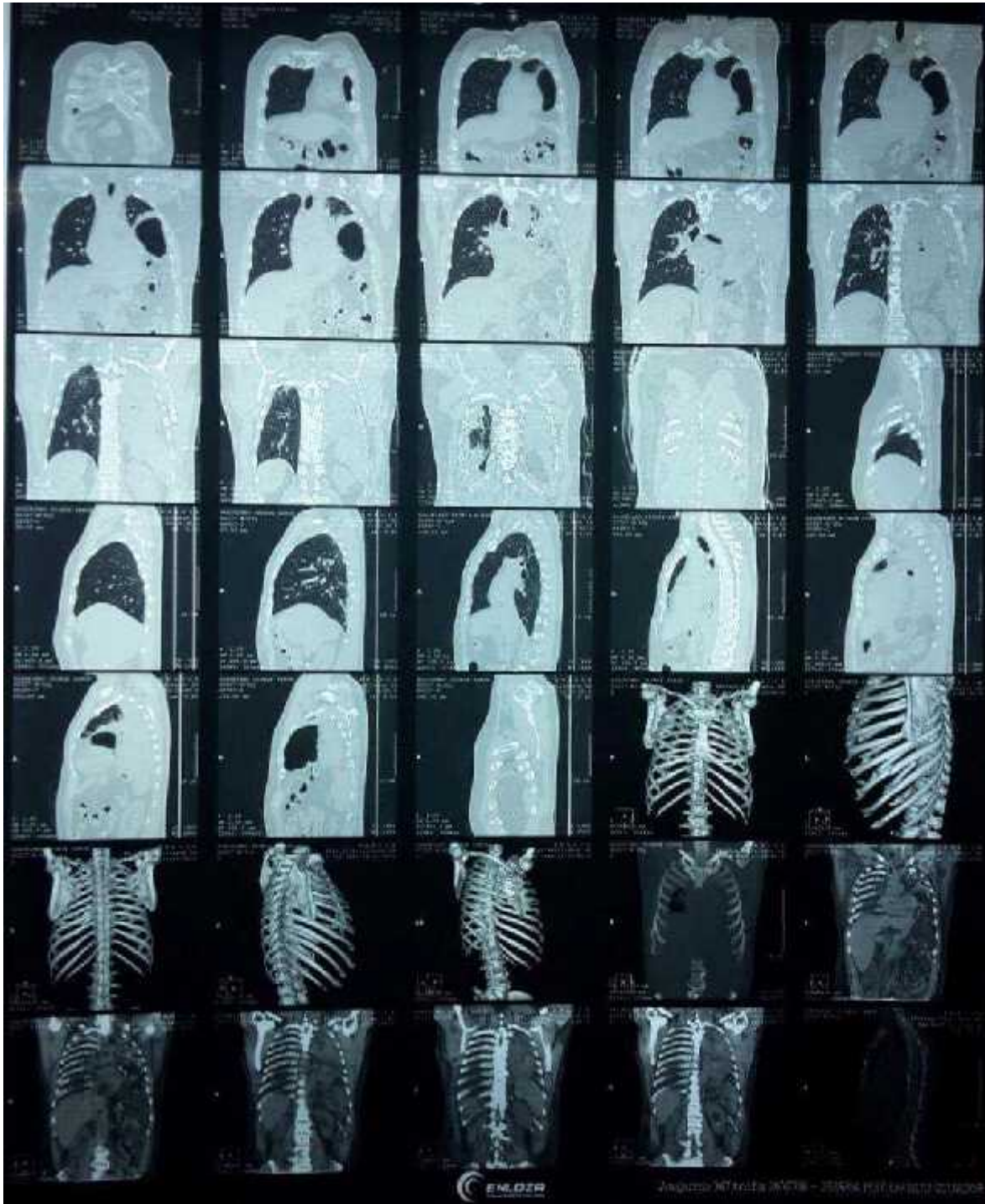


Figure 4. Thoracoabdominal tomography. 3D reconstruction.

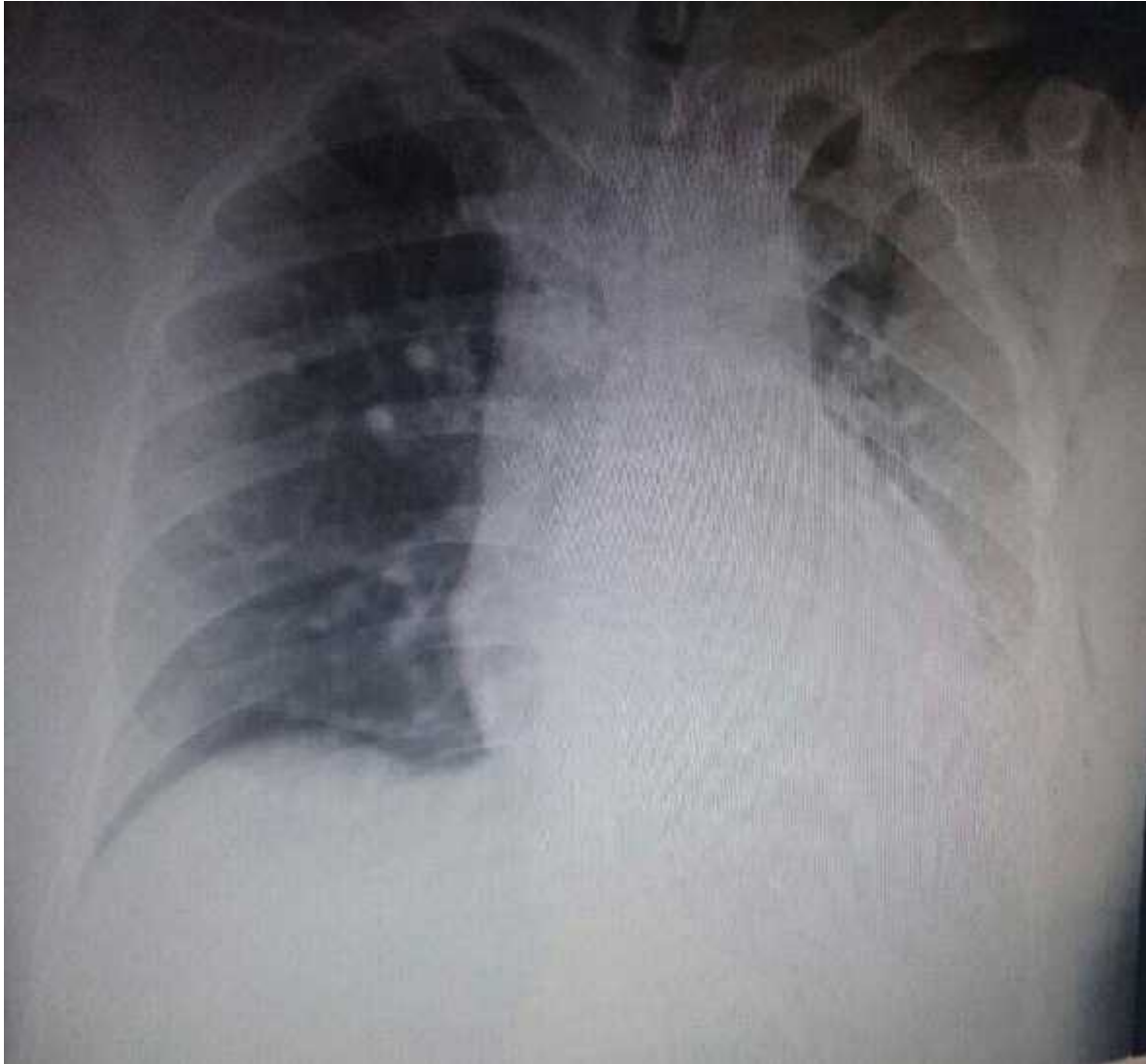

Figure 5. Standard Chest Rx (Control).

## Discussion

Traumatic diaphragmatic hernias, despite being rare, should always be taken into consideration in patients with closed trauma, when it is below the seventh intercostal space; they are more frequent on the left side because on the contralateral side the liver serves as a barrier.

The patient entered the Portoviejo Medical Clinic being stable, without alterations in the respiratory pattern; the hypothesis of acute vs chronic traumatic diaphragmatic hernia remains in the air, but the antecedents of previous traumas, the hemodynamic stability at admission and the radiographic signs, simulate chronic pathology that was complicated on the second



postoperative day by the pulmonary collapse, after increasing the Hernial content in left hemithorax.

The formulated hypothesis is that the anterior traumas produced the diaphragmatic lesion that increased in size, according to the intra-abdominal pressure, of insidious evolution and never had respiratory symptoms, compensating with the contralateral lung and diverting anatomical structures to the right. Then, an acute injury would have caused hemodynamic instability or respiratory failure within the first hours after the traffic accident. Subsequently, after lung collapse due to the increase in hernia content, the respiratory insufficiency caused hemodynamic instability, which led to an emergency thoracotomy. After the repair of the defect in the diaphragm the patient evolved favorably until he received a medical discharge.

It is necessary to take into account the diagnostic possibility of chronic traumatic diaphragmatic hernia in patients with a record of thoracic traumas, since as it was evidenced in this case, the patient had factors that caused the acute increase of the hernia content towards the left hemithorax.

## Conclusions

Chronic diaphragmatic hernia, is a rare pathology that can spend much time underdiagnosed because in most cases it does not cause signs or symptoms that the patient takes into account. Therefore, the personal record is of vital importance, because with these data the diagnosis can be focused. People who have suffered chest traumas have a high incidence of having silent diaphragmatic hernias.

Computed tomography is the diagnostic method of choice, since it also provides the possibility of detecting associated injuries. On the other hand, the gold standard surgical treatment is thoracoscopy, to repair the defect in the diaphragm and to reduce the hernial content that is usually the stomach, except in chronic cases, where open thoracotomy allows greater comfort to release the hernial content.

Chronic diaphragmatic hernias can have acute complications such as pulmonary collapse or strangulation of the organ that occupies the hernial sac; these complications must be treated in an emergent way because they are potentially deadly.

## Acknowledgments and Conflicts of Interest

I thank the patient for the total collaboration I requested for the presentation of the clinical case for educational purposes, and in turn to the Portoviejo Medical Clinic, for their support in the work I have done, clarifying that I have not received any funding for the writing of the article.

## Bibliography

1. Serra, A., Achon, M., Menéndez, D., Carnesoltas, L. Hernia diafragmática postraumática: caso clínico. Medwave. 2013;13(02).

2. González, D., Díaz, G., Vélez, F., González, M., Villegas, E., Correa, J. Hernias diafragmáticas postraumáticas, panorama actual. *IntraMed Journal*. 2015;4(3).
3. Rogelio, S., Felipe, F., Alfredo, G. Hernia diafragmática congénita de presentación tardía: Estudio de cinco casos y revisión de la literatura. *Acta Pediátrica de México*. 2014;34(2):65-72.
4. Gómez, F., Ramos, Á., Bellino, M., Rico, B., Pardal, A., Crespo, G. Yuste, M. Hernias diafragmáticas traumáticas. *Anales de la Real Academia de Medicina y Cirugía de Valladolid*. 2013;1(50):55-69.
5. Alomá, D., Gonzalez, I., Fragoso, M. Neoplasia de pulmón versus hernia diafragmática: Presentación de un caso. *MediSur*. 2014;12(1):112-117.
6. Bayeux, D., Artilles, S., Alvarez, R. Hernia diafragmática postraumática en un anciano. *MEDISAN*, 2016;20(6): 815-819.
7. Cantú, M., de Luna, F., Robles, M. Hernia de Bochdalek complicada con perforación gástrica en un paciente adulto: Reporte de un caso. *Cirujano General*. 2016;38(2):88-91.
8. Dueñas P, Pérez Y. Epidemiología de las hernias diafragmáticas complejas en el Centro Médico ISSEMYM durante el periodo de mayo del 2003 a septiembre del 2012. [pre grado]. Universidad Autónoma De México; 2013.
9. Maldonado, B., Maldonado, L., Maldonado, P. Presentación tardía de hernia diafragmática traumática luego de 20 años de trauma inicial: resolución laparoscópica. *Revista Médica HJCA*. 2014;6(1):84-87.
10. Moreno, A., Morales, G. Vólvulo gástrico por hernia diafragmática crónica. *Revista Chilena de Cirugía*. 2016;68(3):205-207.